

A case of cerebral sparganosis

A T Alibhoy¹, Ruchira Fernando¹ and Fred Perera²

Introduction

Sparganosis is a rare zoonotic infection, caused in humans by sparganum - the second stage or plerocercoid larva of a pseudophyllidean tapeworm of the genus *Spirometra*. Domestic and wild dogs and cats are definite hosts, and humans are accidental intermediate hosts. Subcutaneous tissue is the usual site of infection, but visceral involvement, including brain, is only rarely reported [1, 2].

Human sparganosis has been reported worldwide, but is most common in China, Japan and southeast Asia. The first report of sparganosis from Sri Lanka included 2 cases of subcutaneous infection detected in lumps excised from the groin and the arm [3]. Subsequently, 2 more cases where the entire larva was recovered from the anterior abdominal wall were reported [4]. Here we present the first report of cerebral sparganosis from Sri Lanka.

Case report

A 13-year old boy presented with three focal motor seizures involving his right arm and leg within a period of 3 days. He had been otherwise well and had an unremarkable past history. There was no unusual dietary history nor had he travelled outside the country. Neuro-imaging showed a minimally enhancing mass lesion with significant perilesional oedema in the left frontal lobe (figure 1). His basic blood reports, chest xray and ultrasound scan of the abdomen were normal. Craniotomy and total excision of the lesion was performed and the child has since remained seizure free on carbamazepine.

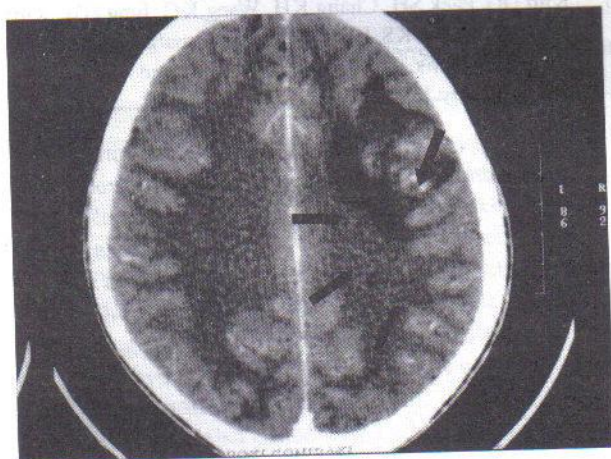


Figure 1. Contrast enhanced CT brain image shows minimal enhancement of the lesion.

Hematoxylin and eosin stained sections revealed a granulomatous reaction consisting of a necrotic area surrounded by histiocytes, neutrophils, plasma cells and eosinophils. The body segments of a cestode larva were seen with the typical pseudosegmentation. The cross sections showed thick cestode tegument with underlying tegument cells. Scattered within the parenchyma were longitudinal strips of muscle bundles and prominent rounded calcareous corpuscles with concentric laminations. A diagnosis of cerebral sparganosis was made based on these findings (figure 2a and 2b).

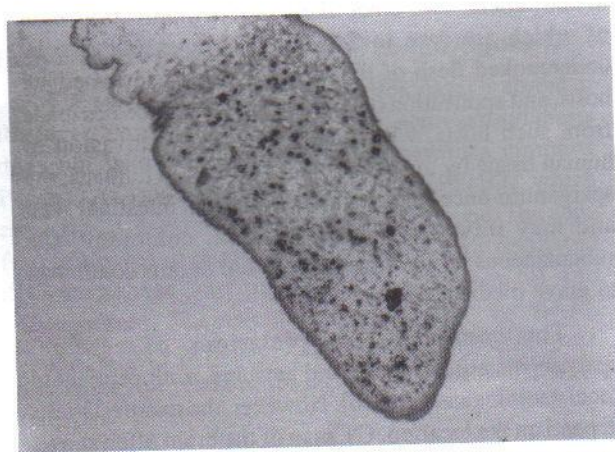


Figure 2a. Section shows a sparganum with typical pseudosegmentation of tegument. H&E x100.

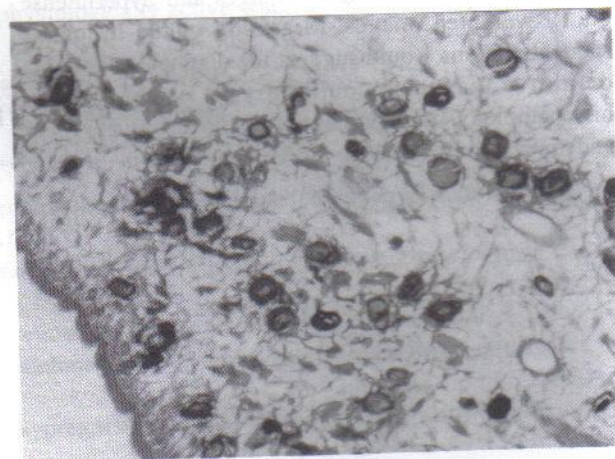


Figure 2b. Section shows stroma containing numerous calcareous corpuscles and longitudinal smooth muscle, and a layer of tegument with subtegument cells. H&Ex400.

¹National Hospital of Sri Lanka, Colombo, ²Asiri Surgical Hospital, Colombo.

Correspondence, ATA, e-mail: <atalibhoy@yahoo.co.uk>. Received 9 March and accepted 27 March 2007.
Competing interests: none declared.

Discussion

The life cycle of *Spirometra* has been well documented [5]. The adult worm lives in the intestines of dogs and cats. When eggs in the faecal matter of these definitive hosts come in contact with water, they hatch into free swimming ciliated coracidia. These are swallowed by a crustacean such as *Cyclops* (first intermediate host) and develop into the first stage or procercoid larvae. Drinking water containing infected *Cyclops* by fish, amphibians and reptiles (second intermediate hosts), results in the larvae developing into a spargana - the second stage or plerocercoid larvae.

Humans are commonly infected by accidentally drinking water contaminated with infected crustaceans. This was the probable mode of infection in the previous cases reported in Sri Lanka, and it is likely to be the same in this patient. Two other likely modes of infection, both of which are rare in Sri Lanka, are eating raw or undercooked flesh of the infected second intermediate hosts, and application of poultices in local remedies made from such hosts, which can cause direct invasion of human tissue by the plerocercoid larvae. In humans, the sparganum once ingested penetrates the intestinal wall and may travel to various viscera, commonly the subcutaneous tissue. Invasion of vital organs could lead to grave medical consequences.

The commonest presentations of cerebral sparganosis are headache and seizures, with or without focal neurological signs [6]. However, the manifestations depend on the location. CT scan of the brain often shows an irregular low density enhancing lesion with prominent perilesional oedema, suggestive of tumour, metastasis or granuloma. MR imaging shows the lesion slightly hypointense on T1-weighted images and hyperintense on T2-weighted images. Migration of the lesion on sequential scans would suggest the diagnosis, though a definitive diagnosis could only be established by histopathology. Immunodiagnosis is not useful except in endemic regions.

There is at present no effective medical therapy for cerebral sparganosis. Early detection and complete surgical excision of the parasite is the best form of treatment [7]. Increased awareness of the infection among medical personnel and educating the public in better personal hygiene, particularly in the use of safe drinking water may prevent infection. This case report expands the geographical distribution of cerebral sparganosis in the world.

Acknowledgement

We thank Prof. N.D. Karunaweera, Professor of Parasitology, Faculty of Medicine, University of Colombo, for assistance in identification of the parasite.

References

1. Holodny M, Almenoff J, Loutit J, Steinberg GK. Cerebral sparganosis: case report and review. *Reviews of Infectious Diseases* 1991; **13**: 155-9.
2. Ausayakhun S, Siriprasert V, Morakote N, Taweasap K. Ocular sparganosis in Thailand. *Southeast Asian Journal of Tropical Medicine and Public Health* 1993; **24**: 603-6.
3. Wijesundera MS, Ratnatunga N, Kumarasinghe MP, Dissanaiké AS. First reports of subcutaneous sparganosis in Sri Lanka. *Ceylon Medical Journal* 1997; **42**: 30-2.
4. Dissanaiké AS, Anthonis PR, Sherifdeen AH, Ihalamulla RL, Karunaweera ND. Two more cases of sparganosis from Sri Lanka. *Ceylon Journal of Medical Science* 2001; **44**: 19-22.
5. Mueller JF. The biology of *Spirometra*. *Journal of Parasitology* 1974; **60**: 3-14.
6. Anders K, Foley K, Stern E, Brown WJ. Intracranial sparganosis: an uncommon infection. *Journal of Neurosurgery* 1984; **60**: 1282-6.
7. Kim DG, Paek SH, Chang KH, Wang KC, Jung HW, Kim HJ, Chi JG, Choi KS, Han DH. Cerebral sparganosis: clinical manifestations, treatment, and outcome. *Journal of Neurosurgery* 1996; **85**: 1066-71.